

Upper Body Regional Exam

Check normal, circle & describe abnormal

CC & significant history: _____

Patient: _____ date: _____

Insurance: _____ (dd/mm/yr)

Date of birth: _____ M/F

Fracture screen (tuning fork, percussion, torsion test): WNL, Refer for imaging: _____

Reflexes: WNL, biceps (C5), brachioradialis (C6), triceps (C7): _____

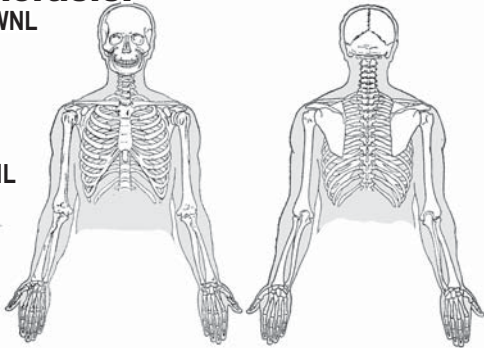
Cervicothoracic:

Observation WNL

- Posture:
- Skin:
- Swelling:
- Asymmetry:

Palpation: WNL

- Soft tissue:
- Bone:
- Lymph nodes:
- Pain:



C-ROM	L -act.- R	L -pas- R	L -res.- R
Flexion (50°)			
Extension (60°)			
Lateral flexion (45°)			
Rotation (80°)			
Temporomandibular joint			
Depres./elevation			
Lateral deviation			

Orthoneuro	L	R
Vaslsalva		
Cervical compress.		
Max. compression		
Cervical distraction		
Soto Hall		
Shoulder depression		
Adson's		
Wright's		
Roo's		

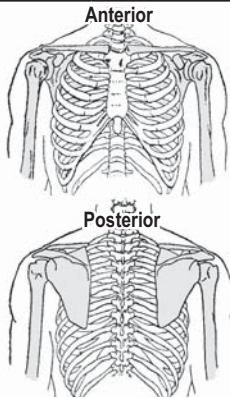
Shoulder:

Observation WNL

- Posture:
- Skin:
- Swelling:
- Asymmetry:
- Step defect:

Palpation: WNL

- Soft tissue:
- Bone:
- Brachial pulse:
- Pain:



ROM/joint play	L -act.- R	L -pas- R	L -res.- R
Flexion (180°)			
Extension (50°)			
Abduction (180°)			
Adduction (30°)			
Internal rotation (90°)			
External rotation (80°)			

Scapulocostal rhythm:

Orthoneuro	L	R
Apley sup./inf.		
Empty can		
Ant. apprehension		
Faegan's		
Hawkins-Kennedy		
Yergason's		
Speeds		
Clunk/crank		
O'Brien		

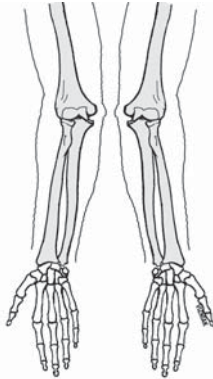
Elbow:

Observation WNL

- Skin:
- Swelling:
- Asymmetry:

Palpation: WNL

- Soft tissue:
- Bone:
- Olecranon bursa:
- Pain:



ROM/joint play	L -act.- R	L -pas- R	L -res.- R
Flexion (150°)			
Extension (0°)			
Supination (90°)			
Pronation (90°)			
Other joint play			
Ulnohumeral			
Radiohumeral			
Proximal radioulnar			

Orthoneuro	L	R
Valgus stress		
Varus stress		
Cozen's		
Mill's		
Book lift test		
Reverse Cozen's		
Reverse Mill's		
Pronator stretch		
Tinel's (ulnar n.)		

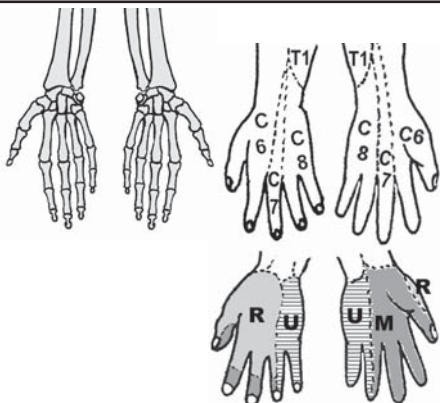
Wrist/hand:

Observation WNL

- Skin:
- Swelling:
- Asymmetry:

Palpation: WNL

- Soft tissue:
- Bone:
- Radial pulse:
- Ulnar pulse:
- Pain:



Wrist ROM	L -act.- R	L -pas- R	L -res.- R
Flexion (80°)			
Extension (70°)			
Ulnar flexion (30°)			
Radial flexion (20°)			
Finger flex./ext.			
Finger add./abd.			
Carpal ROM			
Grip strength			

Orthoneuro	L	R
Phalen's (median)		
Wrist drop (radial)		
Froment's (ulnar)		
Scaphoid fracture		
Bracelet		
Thumb abd. stress		
Thumb grind		
Finklestein's		
Tinel's at wrist x 2		

Signature: _____

Date: _____